

Institutional report - Thoracic non-oncologic Effectiveness of sympathetic block by clipping in the treatment of hyperhidrosis and facial blushing[☆]

Juan J. Fibla*, Laureano Molins, Jose Manuel Mier, Gonzalo Vidal

Department of Thoracic Surgery, Hospital Universitari Sagrat Cor, C/Viladomat 288, Barcelona 08029, Spain

Received 20 May 2009; received in revised form 18 July 2009; accepted 20 July 2009

Abstract

Main cause of dissatisfaction after videothoroscopic (VATS) sympathectomy in the treatment of hyperhidrosis (HH) and facial blushing (FB) is compensatory sweating (CS). Sympathetic nerve (SN) clipping permits to revert the block effect by removing the clips in case of an intolerable CS. We present our experience with this technique. Sixty-one patients diagnosed for HH and/or FB were operated on VATS SN clipping. Clipping levels varied in function for the sort of disease: FB: T2, palmar HH: T3, axillary HH: T4, palmar-axillary HH: T3-4. Results were evaluated 1 week, 3 months and 12 months after surgery. Fifty-eight of the 61 patients showed improvement of their symptoms (95%). There were minor complications in three patients (5.5%). CS was seen in 38/61 (62.2%), being labelled as mild in 33/61 (54%) and severe in 5/61 patients (8.2%), no patient qualified it as intolerable and it was not necessary to remove the clips for CS in any case. SN clipping by VATS is a safe and effective procedure for the management of FB and palmar/axillary HH. Levels of CS are similar or lesser than with the standard sympathectomy and, if necessary, this technique allows to revert the sympathetic block removing the clips.
© 2009 Published by European Association for Cardio-Thoracic Surgery. All rights reserved.

Keywords: Hyperhidrosis; Facial blushing; Sympathectomy; Clipping; Compensatory sweating

1. Introduction

Hyperhidrosis (HH) and facial blushing (FB) cause severe embarrassment, presenting not only psychological and social problems, but also educational and occupational handicaps. Sympathectomy has proved to be a good choice of treatment [1].

Compensatory sweating (CS) is the most common complication of sympathectomy, it is developed in about 30–75% of patients and may be troublesome in 2–3% [2]. The main disadvantage of sympathectomy in this regard is its irreversibility. To date, no operative method has been successful in resolving this problem.

Clipping of the sympathetic nerve (SN) can treat recurrent HH and uncontrollable FB (UFB) and also may resolve the possibly bothersome CS. It can be performed safely and efficiently by a trained thoracoscopist and its results and complications are comparable to the sympathectomy [3].

We used sympathectomy for the treatment of >300 patients since 1996. However, we changed to clipping in the treatment of HH and FB since 2007.

Until now, we found 96 patients undergoing clipping. We present a 1-year follow-up of 61 of them.

2. Methods

The Ethics Committee of our hospital approved this prospective study. From January 2007 to April 2008, 67 patients diagnosed for HH and/or UFB were operated on by videothoroscopic (VATS) sympathectomy. In 61 of them clipping of SN was performed. This procedure was not done in three patients because of technical difficulties – learning curve – and in three because of the patients preference for the classical sympathectomy. All the cases were performed under general anesthesia with single lung ventilation and semi-Fowler position with both arms abducted.

A palmar temperature monitoring was routinely used. Two ports were made. The first 12 mm incision at the anterior axillary line (in the fifth intercostal space) was made for the introduction of a 10-mm 30° thoracoscope (Karl Storz Co) through an obtuse-head trocar. Another 12 mm incision was made along the previous incision scar below each axilla for insertion of a right-angled endoscopic multiple clip applier with 20, 8 mm, titanium clips (Acuclip OMS-A8) through the third or fourth intercostal space. Sometimes, meticulous pneumolysis was needed when we encountered pleural adhesions. Under video assistance, the parietal pleura over the correspondent sympathetic ganglia was opened with the hooked diathermy probe, and the segment of upper sympathetic trunk was identified without transecting the sympathetic trunk (Fig. 1). We performed T2 sympathetic block by clipping for FB, T3 for palmar HH and T4 for axillary HH.

[☆] Presented at the 16th European Conference on General Thoracic Surgery, Bologna, Italy, June 8–11, 2008.

*Corresponding author. Tel.: +34 934948922; fax: +34 934052641.

E-mail address: juanjofibla@hotmail.com (J.J. Fibla).

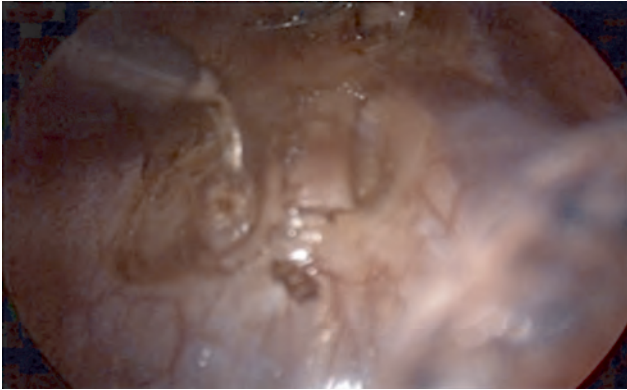


Fig. 1. Opening of the pleura, medially and laterally with circumferential clearance around the SN. SN, sympathetic nerve.

We used Acuclip OMS-A8 Titanium – a right-angled U-shaped endoscopic multiple clip applier (Fig. 2a). During our learning curve, we employed a non-U-shaped applier, finding it difficult on occasions to pass the sympathetic trunk completely with the clip. With the U-shaped applier – similar completely to a TEA for bronchus – we have found it much easier and safe to pass the nerve and clamping it. The three cases not performed with clipping for technical difficulties happened before we started using the U-shaped applier.

The rise of palmar temperature was used as an indicator of correct nerve clipping. When visible, Kuntz nerves were dissected with electro-cautery.

After adequate sympathetic clamping with two clips (Fig. 2b), our anesthesiologist exerted continuous positive pressure for a few seconds to expel the pleural residual air and to prevent possible incomplete expansion of the lung. A single Pleuro-cath drainage was left and connected to a water-seal device with continuous aspiration on both sides and were removed in the operating room (Fig. 2c). The surgical wounds were closed with intradermic suture for cosmetic considerations. A routine chest radiograph was

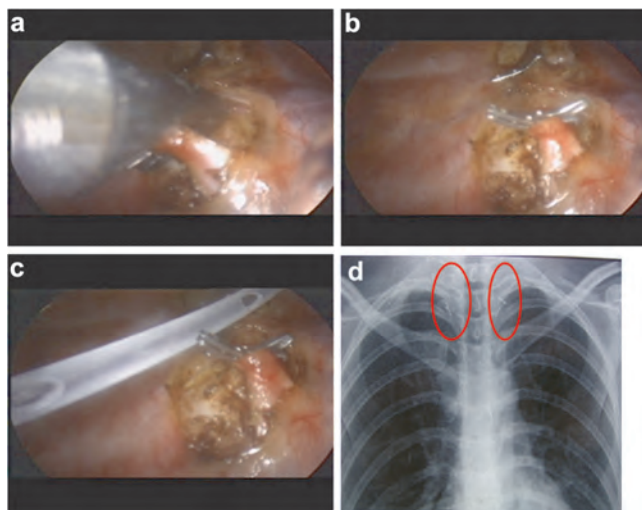


Fig. 2. (a) Endoscopic clip application with the U-shaped applier. (b) Aspect of the SN double clipped. (c) Pleuro-cath drain placed at the end of surgery. (d) Clips visible in the postoperative chest-X-ray. SN, sympathetic nerve.

checked postoperatively to rule out pneumothorax; in this X-ray the correct level of clip placements is visible (Fig. 2d). Patients were discharged 4 h after the procedure.

Results were evaluated one week after the operation in a medical visit, and 3 months and 12 months after surgery with a telephone questionnaire.

3. Results

There were 61 patients, 27 males and 34 females. Mean age: 28 (range 15–47) years. In 15 patients (25%), the main symptom was FB (one patient had been unsuccessfully operated on in another center), in 21 (34%) palmar HH, in 15 (25%) palmar-axillary HH, in 8 (13%) axillary HH, in 1 (1.5%) FB+palmar HH and in 1 (1.5%) facial HH+axillary HH. Palmar temperature rose by >1 °C after clipping SN in all the cases. Fifty-nine of the 61 patients (97%) were discharged within 24 h after the surgery. Forty-two (69%) of them in an ambulatory program. There were complications in three patients (5.5%). One patient was readmitted 72 h after discharge for right pneumothorax that needed drainage. Two patients had persistent air leak during 24 h. In four cases (6.5%), asymptomatic minimal apical postoperative pneumothorax was seen in postoperative chest-X-ray. Discharge was not delayed. They resolved spontaneously in the control chest-X-ray one week after surgery. Fifty-eight of the 61 patients showed improvement of their symptoms (95%).

Three reinterventions were done for technique failure and incomplete response; one case of FB needed placement of an extra clip in the upper part of T2, one case of unilateral axillary HH needed an extra clip at T4, and a bilateral T4 failure also required extra clips at T4. The three cases showed improvement after reintervention.

CS was seen in 38/61 (62.2%), being labeled in the questionnaire as mild in 33/61 (54%) and severe in five patients (8.2%); no patient qualified it as intolerable and clip removal was not demanded. In our historical series of 300 patients submitted to sympathicotomy, we observed an improvement of the symptoms in 99% and CS in 78% being severe in 18%. Up to the present moment, clip removal for insufferable CS has not been needed. On the other hand, in the reoperations we have been able to check the easiness of clip removal.

4. Discussion

The surgical approach to thoracic sympathectomy has evolved from an open procedure requiring hospitalization to a thoracoscopic approach as an outpatient procedure [4]. The most common thoracoscopic technique entails identifying the thoracic sympathetic chain and transecting it sharply or via electro-cautery – sympathicotomy [5].

Despite its efficiency and safety, this procedure has the main disadvantage of being irreversible. The SN conduction is difficult to recover after sympathicotomy and patients might be distressed because of intolerable CS. What is more, some of them may regret the decision of having the surgery performed and might even prefer the original HH or FB.

The treatment options for severe CS after transecting the SN chain are limited. Some investigators suggest using local

injection of botulinum toxin in areas where the sweating is more severe [6]. Telaranta ‘reconstructed’ the SN with sural nerve in five patients with intolerable CS, obtaining good results in four of them. In 1998, he published a case of SN reconstruction with an intercostal nerve graft. In all these cases, he needed a thoracotomy [7]. Recently, in an experimental study with pigs, reconstruction of SN was successfully performed with robotic thoracoscopy [8]. Although promising, these cases are exceptional and, by the moment, SN grafting for reversal of sympathectomy cannot be considered a true option to revert sympathetic block. Although severe CS after transecting SN is estimated to affect only 2–3% of patients, the lack of a real treatment option makes it a serious problem. The surgeon can only offer to wait for spontaneous recovery or subsidence of CS or experimental techniques, and this gives little hope to the patients.

What cannot be forgotten is that, in addition to transection, the interruption of the thoracic sympathetic chain can also be accomplished by clipping. Clinical experience and multiple studies suggest that these methods are equally effective, and this technique offers a true option of treating severe CS [1].

Denny-Brown and Brenner [9] showed in an animal experiment in 1944 that a compression force of >44 g to nerve fiber for two weeks caused failure of conduction of nerve impulses, with a varying degree of loss of myelin sheaths. Lin et al. started the practice of clipping clamping the T2 sympathetic ganglion in 326 patients with palmar HH obtaining excellent results [10]. Since then multiple groups have adopted this technique.

The major potential advantage of clipping (over, by definition permanent transection) is that, if bothersome CS occurs, clip removal is an option.

Clipping is a minimal procedure with limited dissection, the clip(s) on the thoracic sympathetic chain can be readily identified, accessed, and removed at repeat thoracoscopy [11]. Jo et al. have published a technique for clip removal with the patient awake and under local anesthesia [12]. They used a sling of 3-0 propylphylene suture tied to the clip and to the subcutaneous tissue of one of the thoracoports. When unclipping was needed, the clip was removed by pulling it back under portable fluoroscopy.

In our series, no patient needed reversible operation and removal of the clip for intolerable CS, but several large series have published their results after unclipping. The improvement rate ranged from 50 to 100% [10–15].

Regarding the optimal time for clip removal, the general idea is to do it in the first two months after surgery. Therefore, it is crucial to diagnose intolerable CS as soon as possible. Lin and colleagues suggested that the clip should be removed <2 weeks after clipping, before the degeneration of the SN [10]. In contrast, Reisfeld suggested that the removal within six months might be acceptable for obtaining a successful result [13].

The improvement of the symptoms and the nerve regeneration can take a few months or up to a year. Kang et al. observed improvement of CS four weeks after removal [14], however, Lin et al. saw it one year after [10]. Reisfeld in a

series of 25 patients submitted to unclipping because of CS and followed-up during 46 weeks observed maintained improvement in 52% of the cases, and only 28% recovered original HH [15].

Patients expect to be cured from their HH/FB but they fear intolerable CS and like the idea that the procedure might have an option of reversibility.

The effect of clip removal is not 100% effective, and needs to be studied further in larger cohorts; however, the mere fact that the efficacy of clipping and sympathectomy are equivalent, and that reversal is an option only with clipping, should drive thoracic surgeons to this technique.

In conclusion, in our experience SN clipping by VATS has proved to be a safe and effective procedure for the management of FB and palmar/axillary HH. Efficacy and levels of CS are similar than with the standard sympathectomy and, if necessary, this technique allows to revert the sympathetic block removing the clips. Because of these advantages, it is at the present moment our standard procedure for HH/FB treatment.

References

- [1] Henteleff HJ, Kalavrouziotis D. Evidence-based review of the surgical management of hyperhidrosis. *Thorac Surg Clin* 2008;18:209–216.
- [2] Molins L, Simon C, Buitrago J, Vidal G. Surgical treatment of palmar and axillary hyperhidrosis. *Arch Bronconeumol* 2003;39(Suppl 6):50–56.
- [3] Whitson BA, Andrade RS, Dahlberg PS, Maddaus MA. Evolution of clipping for thoracoscopic sympathectomy in symptomatic hyperhidrosis. *Surg Laparosc Endosc Percutan Tech* 2007;17:287–290.
- [4] Fibla J, Molins M, Mier J, Vidal G. Results of videothoroscopic sympathectomy in the treatment of facial redness and hyperhidrosis in 41 patients. *Cir Esp* 2008;83:256–259.
- [5] Baumgartner FJ. Surgical approaches and techniques in the management of severe hyperhidrosis. *Thorac Surg Clin* 2008;18:167–181.
- [6] Bechara FG, Sand M, Moussa G. Treatment of unilateral compensatory sweating after endoscopic thoracic sympathectomy for general hyperhidrosis with botulinum toxin A. *Dermatol Surg* 2006;32:745–748.
- [7] Telaranta T. Secondary sympathetic chain reconstruction after endoscopic thoracic sympathectomy. *Eur J Surg* 1998;164(Suppl 580):17–18.
- [8] Latif MJ, Afthinos JN, Connery CP, Perin N, Bhora FY, Chwajol M, Todd GJ, Belsley SJ. Robotic intercostal nerve graft for reversal of thoracic sympathectomy: a large animal feasibility model. *Int J Med Robot Comput Assist Surg* 2008;4:258–262.
- [9] Denny-Brown D, Brenner C. Lesion in peripheral nerve resulting from compression by spring clip. *Arch Neurol Psychiatr* 1944;52:1–19.
- [10] Lin CC, Mo LR, Lee LS. Thoracoscopic T2-sympathetic block by clipping – a better and reversible operation for treatment of hyperhidrosis palmaris: experience with 326 cases. *Eur J Surg* 1998;164(Suppl 580):13–16.
- [11] Chou SH, Kao EL, Lin CC. The importance of classification in sympathetic surgery and a proposal mechanism for compensatory hyperhidrosis: experience with 464 cases. *Surg Endosc* 2006;20:1749–1753.
- [12] Jo KH, Moon SW, Kim YD. New protocol for a reversal operation in endoscopic thoracic clamping: pulling back the suture sling linked to the clip under local anesthesia. *Surg Laparosc Endosc Percutan Tech* 2007;17:29–32.
- [13] Reisfeld R. Sympathectomy for hyperhidrosis: should we place the clamps at T2-T3 or T3-T4? *Clin Auton Res* 2006;16:384–389.
- [14] Kang CW, Choi SY, Moon SW, Cho DG, Kwon JB, Sim SB, Wang YP, Jo KH. Short-term and intermediate-term results after unclipping. *Surg Laparosc Endosc Percutan Tech* 2008;18:469–473.
- [15] Reisfeld R. Sympathectomy reversal. Clamping vs nerve graft. Eighth International Symposium on Sympathetic Surgery (ISSS), March 25–27, 2009. New York, USA.