



EUROPEAN MUSCULOSKELETAL DISEASE

VOLUME 4 • ISSUE 1

**Transforaminal Endoscopic
Stenosis Surgery –
A Comparative Study
of Laser and Reamed
Foraminoplasty**
Rudolf Morgenstern

*Head, Morgenstern Institute
of Endoscopic Spine Surgery,
Centro Médico Teknon, Barcelona*

Transforaminal Endoscopic Stenosis Surgery – A Comparative Study of Laser and Reamed Foraminoplasty

Rudolf Morgenstern

Head, Morgenstern Institute of Endoscopic Spine Surgery, Centro Médico Teknon, Barcelona

Abstract

This article presents a new endoscopic procedure: transforaminal endoscopic stenosis surgery (TESS). This technique is performed through a posterolateral transforaminal approach and allows the foramen in a collapsed lumbar disc to be widened by undercutting the superior facet under direct endoscopic control. A new endoscopic small reamer is used for this purpose, which allows the aggression to the surrounding tissues to be minimised. This study of 216 cases of lumbar foraminal stenosis compares the results of one group in which the new endoscopic bone reamers were used for the foraminoplasty with the results of another group in which only classic foraminoplasty was performed with a standard holmium: yttrium–aluminium–garnet (Ho:YAG) laser. The methods were as follows: 216 patients with lumbar foraminal stenosis underwent endoscopic spine surgery from 2003 to 2008 at Centro Médico Teknon in Barcelona. One hundred and twenty-five patients underwent classic endoscopic surgery, i.e. only a Ho:YAG laser was used for the foraminoplasty (Group A); 91 patients underwent TESS, i.e. the new endoscopic bone reamers were used for the foraminoplasty (Group B). The inclusion criteria were unilateral or bilateral radicular leg pain associated with imaging evidence of foraminal or lateral stenosis, and inadequate response to conservative treatment for >6 months. All 216 procedures were performed in the prone position and under local anaesthesia. Pain was scored for every patient both pre- and post-operatively using a visual analogue scale (VAS); disability was scored using the Oswestry Disability Index (ODI). The post-operative scores were updated every three months. The mean follow-up period was 2.8 years (range: six to 61 months). The results were as follows: 216 patients who met the inclusion criteria underwent TESS. These 216 patients comprised 143 men and 73 women with ages ranging from 17 to 82 years (mean age 45.8 years). The overall results, evaluated according to Macnab criteria, for the 216 cases were: 151 excellent (69.9%), 45 good (20.8%), 16 fair (7.4%) and four poor (1.9%). The results for group A (125 cases) were: 90 excellent (72%), 20 good (16%), 14 fair (11.2%) and one poor (1.9%). The results for group B (91 cases) were: 61 excellent (67%), 25 good (27.5%), two fair (2.2%) and three poor (3.3%). The average surgical time was approximately 50 minutes for group A and approximately 30 minutes for group B.

Keywords

Spinal endoscopy, minimally invasive spine surgery, transforaminal endoscopic surgery, endoscopic stenosis surgery, endoscopic laser foraminoplasty, endoscopic reamed foraminoplasty

Disclosure: The author receives payments from joimax GmbH for consulting activities, as well as royalty fees.

Received: 11 October 2008 **Accepted:** 8 December 2008

Correspondence: Rudolf Morgenstern, Orthopaedic Spine Surgery, Centro Médico Teknon, E-08034 Barcelona, Spain. E: rudolf@morgenstern.es

The first posterolateral discectomy was a percutaneous central nucleotomy and was reported by Hijikata¹ in 1975, followed by Kambin and Gellman's² report of nine cases in 1983. In 1983, Forst and Hausmann³ described the direct visualisation of intervertebral disc space with a modified arthroscope. Schreiber et al.⁴ used a biportal endoscopic technique. In 1996, Mathews⁵ wrote about the transforaminal approach, but it is the same portal utilised by Kambin⁶ and Yeung.⁷

To aid visualisation, Yeung⁷⁻⁹ used a laser as an adjunct to endoscopic discectomy. Yeung⁸ and Knight¹⁰ later used the holmium: yttrium–aluminium–garnet (Ho:YAG) laser for foraminoplasty and decompression of stenosis (endoscopic laser foraminoplasty [ELF]). In 1997, Yeung⁷⁻⁹ introduced a rigid rod-lens, flow-integrated and multichannel operating spinal endoscope with slotted and bevel-ended cannulas that allowed for same-field viewing of the epidural space, annular wall and intradiscal space. Hijikata¹ in 1989, Kambin et al.,⁶ Mathews⁵ in 1996, Yeung et al.^{7,8} and Tsou et al.⁹ in 2002 reported

on the posterolateral approach for intradiscal access employing the transforaminal technique.

Schreiber et al.¹¹ in 1989, Mayer and Brock¹² in 1993, Hermantin et al.¹³ in 1999 and Ruetten¹⁴ in 2008 compared the percutaneous endoscopic discectomy with microsurgical discectomy and open conventional discectomy. All of them concluded that the outcome of endoscopic discectomy was similar to the conventional discectomy, but the endoscopic procedure was less invasive and less aggressive to the surrounding tissue than the open surgery.

In 2003 Ahn et al.¹⁵ and Hoogland¹⁶ introduced new techniques to perform foraminoplasty using a transforaminal posterolateral approach that allowed reaming out the capsule and the foraminal ligament by undercutting the cranial part of the superior facet.

In this article, we will present a new endoscopic surgical procedure, which we call transforaminal endoscopic stenosis

surgery (TESS). This technique is used to widen the foramen through a posterolateral transforaminal approach, reaming out the capsule and the foraminal ligament by undercutting the cranial part of the superior facet under direct endoscopic control using a new endoscopic small reamer (endoreamer) with minimal aggression to the surrounding tissues. The endoscopic surgical procedure itself is similar to the surgical technique previously described by Yeung et al.,⁸ Lee et al.¹⁷ and others,^{18,19} but with the additional use of bone reamers, as described by Ahn et al.¹⁵ and Hoogland,¹⁶ to perform foraminoplasty, especially at L5–S1. This study of transforaminal endoscopic foraminoplasty, comprising a total of 216 cases of lumbar lateral or foraminal stenosis, compared the results of one group of patients on which bone reamers were used for the foraminoplasty with the results of another group of patients on which only a Ho:YAG laser was used to widen the bony foramen.

Materials and Methods

Patient Selection

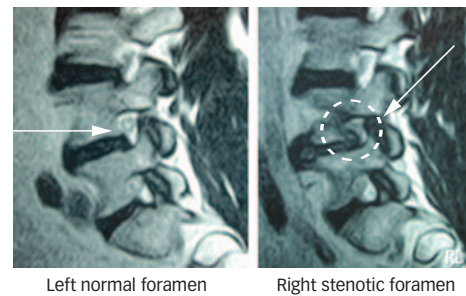
The current author performed surgery on a total of 216 patients between January 2003 and December 2007 at Centro Médico Teknon in Barcelona, Spain. Of these patients, 125 underwent posterolateral transforaminal endoscopic surgery using Ho:YAG laser for foraminoplasty (group A), and 91 underwent posterolateral TESS with bone reamers and endoreamers for foraminoplasty (group B).

The inclusion criteria for endoscopic surgery were unilateral or bilateral radicular leg pain associated with foraminal or lateral stenosis (see *Figure 1*) and an inadequate response to conservative treatment for >6 months. The exclusion criteria were intervertebral instability, central stenosis, bone infection, drug abuse and tumours. Scoliosis was not an exclusion criterion. The general inclusion criteria required clinical evidence of lumbar foraminal or lateral stenosis (associated or not associated with a disc herniation) and findings from a physical examination consistent with the magnetic resonance imaging (MRI) findings. Every patient had had at least six months of failed non-surgical treatment and clinical signs of radiculopathy, which included intractable leg or buttock pain with or without back pain. Lumbar sagittal and frontal X-rays and MRI were the standard minimal images used to correlate symptoms of back and neuropathic pain.

To perform an endoscopic transforaminal approach, it is necessary to first insert a needle into the disc. The addition of discography as a complementary step provides additional information to confirm that the disc is painful under increased internal pressure. It also helps to verify the herniation shape, if present, and stains the degenerative nucleus pulposus blue with a vital dye (indigo carmine) for targeted disc extraction. The entire procedure is performed under local anaesthesia and light patient sedation so that the patient is able to respond to simple verbal orders and react to pain stimuli.

Routine pre-operative electrocardiogram (ECG), thorax X-ray and blood analysis were systematically performed for every patient. All medical records were carefully reviewed and neurological examinations were performed pre- and post-operatively. All patients underwent pre-operative MRI and anterior–posterior (A/P) and lateral lumbar spine X-ray.

Figure 1: Magnetic Resonance Imaging Sagittal View of L4–L5 in a Patient with Unilateral Right Foraminal Stenosis



Surgical Technique

All 216 procedures were performed in a prone position by posterolateral transforaminal approach under endoscopic control. The patient was placed in a prone position with slight hip flexion on a radiolucent table. The skin was anaesthetised with lidocaine 1% and the patient was kept conscious under light sedation during the surgical procedure. The skin-entry point was chosen and an 18G needle was located following Yeung's⁹ technique. A contrast discography with indigo carmine (Taylor Pharmaceuticals, Decatur, Illinois) diluted with iopamidol 300 1:10 was performed to blue-stain abnormal nucleus pulposus and annular fissures.

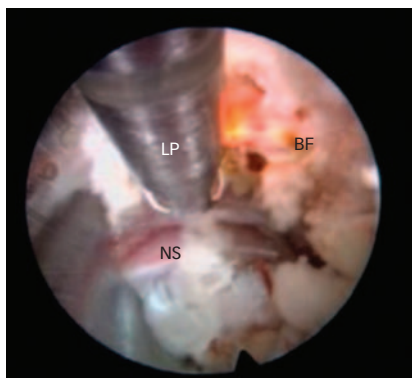
Surgical Procedure for Group A

Under the endoscopic procedure, the foraminoplasty was performed as described by Yeung¹⁻³ using a 20° rigid endoscope with a working channel of 2.8mm (YESS; Richard Wolf GmbH, Knittlingen, Germany), laser Ho:YAG 80W with 90° side-firing electrodes (Trimeddyne Inc., Irvine, California), radiofrequency coagulation system (Ellman International Inc., Hewlett, New York) and indigo carmine (Taylor Pharmaceuticals, Decatur, Illinois) diluted with iopamidol 300 1:10 to blue-stain abnormal nucleus pulposus and annular fissures.⁸

In accordance with the procedure, after the needle insertion and the discogram, a dilator is passed using the needle central guide. This central guide is then extracted and a 30° bevelled cannula is passed over the dilator and the dilator extracted. The fluoroscopy X-ray arch is used to control in A/P and lateral view the proper position of the dilator and cannula into the disc through the foraminal approach; the endoscope is then passed through the cannula and, under saline irrigation, the disc and foraminal structures are visible on the camera monitor.

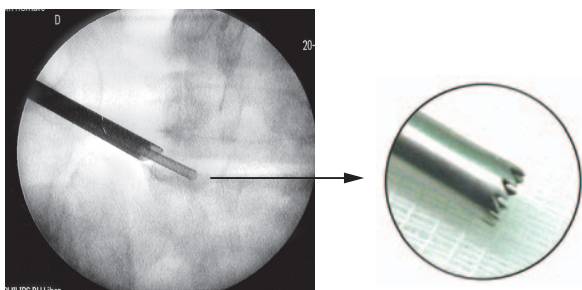
The careful dissection of the ligament and disc tissues with laser energy and single-action basquets allows the surgeon to see the blue-stained nucleus pulposus and the herniation, if present, and, with careful identification, the neural structures. A foraminoplasty was performed with the Ho:YAG laser to ablate the cranial part of the superior facet and the articular capsule (see *Figure 2*). The laser was set to an output of 80W and limited to a maximum duration of 120 seconds (9,600J per session). The area of exposure was the caudal foraminal region, as the laser was used to ablate all soft tissues (ligament and capsula) and 2 or 3mm of the bony facet. After the herniation removal (if present) and a disc curettage of the remaining nuclear loose or degenerated fragments, the endoscope can be removed and the skin sutured (5mm).

Figure 2: Endoscopic View of Side-firing Laser Probe



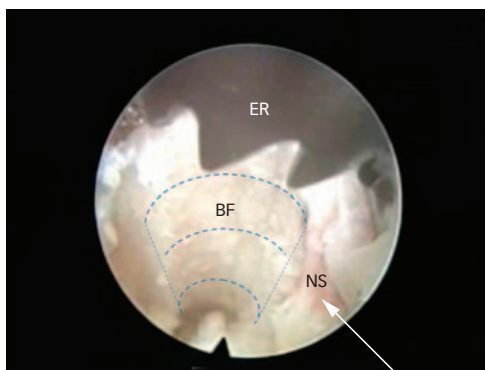
Endoscopic view of the 90° side-firing laser probe (LP) (upper left side) undercutting the bony facet (BF) by direct visual control. This allows the decompression of the neural structure (NS) located on the bottom of the image without the possibility of harmful side effects.

Figure 3: Anterior–Posterior X-ray View of Endoscopic Reamer



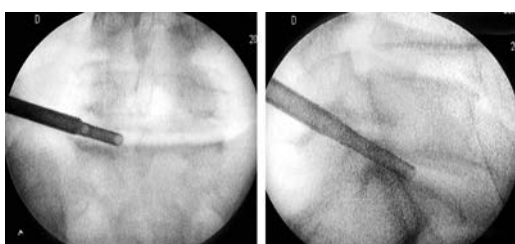
Anterior–posterior fluoroscopic view of the 3.5mm-diameter endoscopic reamer undercutting the facet at L5–S1 in a patient with unilateral foraminal stenosis. The endoscope's tip is reaching out of the guiding cannula and the reamer is passing through the endoscope's working channel into the neuroforamen.

Figure 4: Endoscopic View of Endoscopic Reamer



Endoscopic view of the 3.5mm-diameter endoscopic reamer (ER) (upper right side) undercutting the bony facet (BF) by direct visual control. This allows the decompression of the neural structure (NS) located on the right side of the image (see arrow) without the possibility of harmful side effects.

Figure 5: 5mm-diameter Reamer Cutting the Facet Under Cannula Protection



Surgical Procedure for Group B

The reamed foraminoplasty under endoscopic procedure was performed using a 30° endoscope with an outer diameter of 6.3mm and a working channel of 3.7mm (joimax GmbH, Karlsruhe, Germany) that was inserted through the foramen to visually identify the superior facet. Progressive tissue dilatation was achieved by placing a bevelled cannula with 7.5mm of outer diameter (joimax GmbH, Karlsruhe, Germany) in immediate contact with the foraminal border of the annulus.

A new endoscopic bone reamer with a 3.5mm outer diameter (Morgenstern Stenosis System, joimax GmbH, Karlsruhe, Germany) was introduced through the endoscope's working channel (3.7mm diameter) to undercut the superior facet (see *Figures 3 and 4*). This new reamer (outer diameter 3.5mm) allowed sculpturing of the facet through the endoscope's working channel under direct endoscopic visual control despite the narrow space available in the collapsed foramen. In doing so, it was possible to enlarge the foramen without touching or harming the neural structures. This new endoscopic reaming technique was developed by joimax in co-operation with the current author so that foraminoplasty could also be performed in narrow neuroforamens.

After protecting the exiting root by rotating the bevelled cannula (see Tsou et al.⁹ and Ahn et al.¹⁵), the endoscope was withdrawn. This allowed the surgeon to pass a 5mm bone reamer (joimax GmbH, Karlsruhe, Germany) through the bevelled cannula to ream out the bony facet. The reamer is advanced under fluoroscopic control until it reaches the medial pedicular line (A/P projection) (see *Figure 5*). After removing the reamer, the endoscope was used again to remove remnant bone fragments with an endoscopic basket (joimax GmbH, Karlsruhe, Germany), while ligament and soft tissue was removed with a radiofrequency electrode (Ellman Innovations LLC, Oceanside, New York), also used to coagulate blood vessels or inflammatory tissue. After clearing the way to the intervertebral space, degenerated nuclear material, if present, was removed.

Finally, in both procedures (group A and group B) the endoscope was used to visually confirm the decompression of the exiting nerve root. Additionally, the exiting root can be mobilised under direct endoscopic vision with a flexible probe (joimax GmbH, Karlsruhe, Germany and Ellman Innovations LLC, Oceanside, New York) to confirm the decompression. Interestingly, it has also been observed, directly through the endoscope, that the exiting nerve root usually pulses at heart rate when decompressed. After retrieving the endoscope, the skin was sutured and A/P and lateral fluoroscopic controls were printed for the case's records. A corticoid such as Depomedrol 125mg is locally injected before the skin suture.

In 125 cases (patient group A) the surgical procedure was performed as described, using the laser for the bony foraminoplasty (see *Figure 2*). For 91 cases (patient group B), the surgical procedure was performed as described, but using the reamers for the bony foraminoplasty (see *Figure 4*).

Patient selection criteria did not vary between group A and group B. For both groups, approximately four hours after surgery most of the patients had started walking and approximately 12 hours after surgery the patients had been discharged. Additional A/P and lateral X-ray control on the lumbar spine was performed for each

patient five to six months after surgery. The surgical time evolution was recorded for both procedures. The surgical time is the time elapsed between the first needle puncture and the final skin suture. To minimise the influence of the number of operated discs and the difficulty of every single case, the surgical time was averaged every 20 cases.¹⁸

Outcome Evaluation

Pain was scored with a visual analogue scale (VAS) and the disability was evaluated with the Oswestry Disability Index (ODI) for every patient. The scoring was performed pre- and post-operatively for the VAS and the ODI score. The post-operative scores were updated every three months to achieve a minimal follow-up of 18 months for every case.

The scoring was performed anonymously by independent professional physiotherapists who routinely participate in the rehabilitation of the surgeon's patients.²⁰ Standard pre- and post-operative neurological and clinical examinations were performed by the authors for every case immediately (maximum one hour) after the operation and were repeated after 24 hours and again 30 days after the surgical procedure. If neurological symptomatology (paresia, dysesthesia, hyposthesia, etc.) was detected, electromyography (EMG) controls were additionally performed in every evaluation. The mean follow-up period was 33.8 months (2.8 years) (range six to 61 months), as can be seen in *Table 1*. Finally, follow-up Macnab²¹ criteria were applied to classify the outcome of the cases.

Results

Two hundred and sixteen patients who met the inclusion criteria underwent TES surgery, comprising 143 men and 73 women with ages ranging from 17 to 82 years (mean age 45.8 years) (see *Table 1*). The 216 operated patients were divided into two groups: 125 patients with laser foraminoplasty (group A) and 91 patients with bone-reamed foraminoplasty (group B). The age distribution of both groups was similar, as the mean age of group A was 45.78 years and the mean age of group B was 45.92 years. The operated disc distribution can be seen in *Table 2*.

The overall outcome results, as well as the separate outcome results for both groups evaluated according to Macnab²¹ criteria, are shown in *Table 3*. The overall outcome (216 cases) was: 151 excellent (69.9%), 45 good (20.8%), 16 fair (7.4%) and four poor (1.9%). The outcome of group A (125 cases) was: 90 excellent (72%), 20 good (16%), 14 fair (11.2%) and one poor (0.8%) (see *Table 3*). The outcome of group B (91 cases) was: 61 excellent (67%), 25 good (27.5%), two fair (2.2%) and three poor (3.3%) (see *Table 3*). The overall mean values of the VAS and ODI scores, as well as the scores for both groups, can be found in *Table 4*. In both groups, some cases of transitory dysaesthesia were reported (<10%). These neurological phenomena disappeared after two to four weeks of treatment with oral corticoids in all cases. The average surgical time was 50 minutes for group A, compared with 30 minutes for group B. No dural tears, neurological damage or wound infections were reported.

Discussion

When the disc height collapses, the cranial part of the superior facet ascends, narrowing the foramen and compressing the neural exiting structures, as has also been observed by Maher and Henderson²² and Rauschnig.²³

Table 1: Patient Statistics

Patients	Male	Female	Total
Number of patients	143	73	216
Mean age (years)	44.9	47.6	45.8
Age range (years)	22–78	17–82	17–82
Mean follow-up (months)	33	34	33.8
Follow-up range (months)	6–60	7–61	6–61

Table 2: Operated Disc Distribution

Patients	Total	Group A	Group B
L3–L4	31	26	5
L4–L5	100	50	50
L5–S1	85	49	36
Cases Σ	216	125	91

Table 3: Results

Number	216	%	125	%	91	%
	Total		Group A		Group B	
Excellent	151	69.9	90	72	61	67
Good	45	20.8	20	16	25	27.5
Fair	16	7.4	14	11.2	2	2.2
Poor	4	1.9	1	0.8	3	3.3

Table 4: Visual Analogue Scale and Oswestry Scores

Scores	VAS		ODI	
	Pre-op.	Post-op.	Pre-op.	Post-op.
Total scores (216 cases)	7.6	29.3	2.5	10.3
Group A (125 cases)	7.7	30.2	2.9	12
Group B (91 cases)	7.5	28.1	2	8

VAS = visual analogue scale; ODI = Oswestry disability index.

According to Jenis et al.,²⁴ the most common (75%) reported level of foraminal stenosis is at L5–S1. However, Ahn et al.¹⁵ reported that "in terms of L5-S1 level, the number of cases... (operated by others) ... has been relatively small, because access at this level is considered too difficult as the iliac crest and/or L5 transverse process act as obstacles." Subsequently, Ahn et al.¹⁵ described a new endoscopic technique using a bone reamer for undercutting the superior facet, especially at L5–S1. This technique is more effective and time-saving than previous techniques¹⁰ due to the combined action of the bone reamer and the side-firing Ho:YAG laser. However, this technique uses indirect endoscopic control of the reaming only, as it alternates reaming through the cannula (only under X-ray C-arm control) and the endoscopic vision. However, in extremely collapsed discs (>50% of total disc height), the dorsal root ganglion, the exiting nerve root and, in many cases, a herniated portion of the nucleus and/or disc tissue with excess foraminal ligament and capsula may fill the foramen and increase the difficulty of introducing an endoscope. For these narrow spaces, it is imperative to perform the reamed foraminoplasty under direct endoscopic vision in order not to harm the neural structures. This is why 91 patients in this study (group B) were operated on using a new endoscopic 3.5mm bone reamer for undercutting the superior facet under direct endoscopic vision. It is worth noting that 36 patients were operated at level L5–S1. The remaining 125 patients (group A) underwent surgery with the classic and supposedly less efficient laser foraminoplasty technique.⁷⁻⁹

The control variables of this study were the VAS and ODI scores and the clinical outcome. Failures were determined in terms of recurrent leg pain and/or low-back pain incidence. Poor or fair results had clinical relevance only when the post-operative VAS scores reached values ≥ 5 and/or the post-operative ODI scores were >25 . Therefore, the evolution of the 216 patients was clinically controlled every three months for a total of 18 months for every individual case.

In this article, we present a new endoscopic surgical procedure, which we call transforaminal endoscopic stenosis surgery.

The final surgery outcome was similar for both techniques: laser foraminoplasty achieved excellent and good results in 88%, while the reamed foraminoplasty achieved excellent and good results in 94.5%. Therefore, the new surgical technique presented in this article seems to be promising and useful for narrow foramens in which access is generally difficult. Only after using the 3.5mm reamer under direct endoscopic vision, the 5mm bone reamer (without endoscopic vision) can be used in the already widened foramen, as described by Ahn et al.¹⁵ The endoscopic-controlled reaming of the foramen, as previously described, should therefore be considered an important first step for a successful nerve-root decompression.

Additionally, the surgical time for group A was similar to the time previously reported by the author¹⁸ and also by others.⁸ However, laser foraminoplasty as performed for group A is, in comparison with the surgical time achieved with the reamed foraminoplasty of group B, a more time-consuming technique due to the difficulty of ablating bone only with the laser beam (maximum 0.4mm of penetration). Therefore, the reamed technique used for group B is more effective and time-

saving than the laser foraminoplasty techniques⁷⁻¹⁰ thanks to the radical action of the bone reamer for foraminoplasty.

Conclusions

This study has demonstrated the efficacy and efficiency of a new surgical technique (TESS) for foraminal stenosis that uses bone reaming under direct endoscopic control to widen the foramen in cases of foraminal or lateral stenosis. This endoscopic technique appears to be more accurate than other reaming techniques that are used only with X-ray C-arm control and not under direct endoscopic vision. Similar outcome and scoring results were achieved for the reamed and laser bone foraminoplasty, but the latter was less efficient as it presented longer average surgical time (an average of approximately 20 minutes or more) and higher material costs.

This new endoscopic-reamed technique opens the way for surgeons to primarily avoid more aggressive methods of decompression and minimise the surgical costs. ■

Reprint Citation: Morgenstern R, Transforaminal Endoscopic Stenosis Surgery – A Comparative Study of Laser and Reamed Foraminoplasty, *European Musculoskeletal Review*, 2009;4(1) in press.



Rudolf Morgenstern is Head of the Morgenstern Institute of Endoscopic Spine Surgery at Centro Médico Teknon in Barcelona and an orthopaedic surgeon in private practice. He specialises in percutaneous endoscopic implants for degenerative spine problems and has 28 years of experience in orthopaedic surgery. Dr Morgenstern is an active member of several scientific societies dedicated to spine surgery in Europe and the US. He has published over 15 international papers and has made more than

150 contributions at international conferences related to spine surgery and biomechanics. He has also received several international and national scientific awards for his extensive scientific work. He is a former Associate Professor of Anatomy and Biomechanics at the School of Medicine of the University of Barcelona (UB). He holds an MD from UB and a PhD in mechanical engineering from the Polytechnic University of Catalonia.

- Hijikata S, Percutaneous nucleotomy. A new concept technique and 12 years' experience, *Clin Orthop*, 1989;238: 9–23.
- Kambin P, Gellman H, Percutaneous lateral discectomy of the lumbar spine: a preliminary report, *Clin Orthop Relat Res*, 1983;174:127–32.
- Forst R, Hausmann G, Nucleoscopy: a new examination technique, *Arch Orthop Traum Surg*, 1983;101:219–21.
- Schreiber A., Suezawa Y, Leu H, Does percutaneous nucleotomy with discoscopy replace conventional discectomy? Eight years of experience and results in treatment of herniated lumbar disc, *Clin Orthop*, 1989; 238:35–42.
- Mathews HH, Transforaminal endoscopic microdiscectomy, *Neurosurg Clin N Am*, 1996;7:59–63.
- Kambin P, Casey K, O'Brien E, et al., Transforaminal arthroscopic decompression of lateral recess stenosis, *J Neurosurg*, 1996;84:462–7.
- Yeung AT, The evolution of percutaneous spinal endoscopy and discectomy, *Mount Sinai J Med*, 2000;67: 327–32.
- Yeung AT, Tsou PM, Posterolateral Endoscopic Excision for Lumbar Disc Herniation: Surgical Technique, Outcome, and Complications in 307 Consecutive Cases, *Spine*, 2002;27(7): 722–31.
- Tsou PM, Yeung AT, Transforaminal endoscopic decompression for radiculopathy secondary to intracanal noncontained lumbar disc herniations: outcome and technique, *Spine J*, 2002;2:1.
- Knight MTN, Goswami AKD, Endoscopic laser foraminoplasty. In: Savitz MH, Chiu JC, Yeung AT (eds), *The Practice of Minimally Invasive Spinal Technique. First ed.*, Richmond, VA: AAMISMS Education, LLC, 2000;42:337–40.
- Schreiber A, Suezawa Y, Leu H, Does percutaneous nucleotomy with discoscopy replace conventional discectomy? Eight years of experience and results in treatment of herniated lumbar disc, *Clin Orthop Relat Res*, 1989;(238):35–42.
- Mayer H, Brock M, Percutaneous endoscopic discectomy. Surgical technique and preliminary results compared to microsurgical discectomy, *J Neurosurg*, 1993;78:216–25.
- Hermanting F, Peters T, Quartararo L, Kambin P, A prospective, randomized study comparing the results of open discectomy with those of video-assisted arthroscopic microdiscectomy, *J Bone Joint Surg*, 1999;81(7):958–65.
- Ruetten S, Komp M, Merk H, Godolias G, Full-Endoscopic Interlaminar and Transforaminal Lumbar Discectomy Versus Conventional Microsurgical Technique, *Spine*, 2008;33(9):931–9.
- Ahn Y, Lee SH, Park WM, et al., Posterolateral percutaneous endoscopic lumbar foraminotomy for L5-S1 foraminal or lateral exit zone stenosis. Technical note, *J Neurosurg*, 2003;99(Suppl. 3):320–23.
- Hoogland T, Transforaminal endoscopic discectomy with foraminoplasty for lumbar disc herniation, *Surgical Techniques in Orthopaedics and Traumatology*, 2003;C40: 55–120.
- Lee S, Kim SK, Lee SH, Shin SW, New surgical techniques of percutaneous endoscopic lumbar discectomy for migrated disc herniation, *Joint Disease and Related Surgery*, 2005;16(2):102–10.
- Morgenstern R, Morgenstern C, Yeung AT, The Learning Curve in Foraminal Endoscopic Discectomy: Experience Needed to Achieve a 90% Success Rate, *Journal of the Spine Arthroplasty Society*, 2007;1(3):1–8.
- Morgenstern R, Lavignolle B, Chirurgie endoscopique du rachis lombaire par voie postero-laterale transforaminale, *Le Rachis*, 2007;3:5–6.
- Morgenstern R, Morgenstern C, Abelló A, et al., Eine Studie von 144 Fällen nach unterzogener endoskopischer Lendenwirbelsäulen-chirurgie. Klassische Rehabilitation im Vergleich zur FPZ Methode, *Orthopädische Praxis*, 2005;12: 674–81.
- Macnab I, Negative disc exploration, An analysis of the causes of nerve-root involvement in sixty-eight patients, *J Bone Joint Surg Am*, 1971;53:891–903.
- Maier CO, Henderson FC, Lateral exit zone stenosis and lumbar radiculopathy, *J Neurosurg (Spine 1)*, 1999;90:52–8.
- Rauschnig W, Normal and pathologic anatomy of the lumbar root canals, *Spine*, 1987;12:1008–19.
- Jenis LG, An HS, Gordin R, Foraminal stenosis of the lumbar spine: a review of 65 surgical cases, *Am J Orthop*, 2001;30:205–11.

TESSYS[®]

Transforaminal Endoscopic Surgical System

- > Fragmentectomy
- > Foraminoplasty
- > Decompression
- > Nucleotomy
- > Annuloplasty
- > Discography

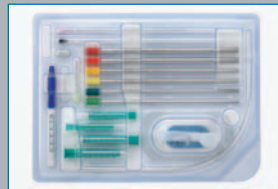TES[®] - Transforaminal Endoscopic Surgery with TESSYS[®] – the Unique All-in-One System

joimax[®] Digital Endoscopic System


joimax[®] provides the latest digital technology for endoscopic surgery, particularly for innovative „joined minimal access“ procedures.




TESSYS[®] Instrument Sets




TESSYS[®] Disposable Access Kits




TESSYS[®] Foraminoscope



Surgi-Max[™] Trigger-Flex[™] RF-Probes



TESSYS[®] Spinal Stenosis Set acc. to Dr. R. Morgenstern



iLESSYS[™] interLaminar Endoscopic Surgical System

joined minimal access technologies

CESSYS[™]
Cervical Endoscopic Surgical System

TESSYS[®]
Transforaminal Endoscopic Surgical System

+ **TESSYS[®] Spinal Stenosis**
Transforaminal Endoscopic Surgical System
for Spinal Stenosis Treatment acc. to Dr. R. Morgenstern

+ **iLESSYS[™]**
Interlaminar Endoscopic Surgical System

+ **New MISS Implants**

+ **Neuro Monitoring**

joimax[®] GmbH

An der RaumFabrik 33a,
Amalienbadstraße 36
76227 Karlsruhe - Germany

PHONE +49 (0) 721 255 14-0
FAX +49 (0) 721 255 14-920
MAIL info@joimax.com
NET www.joimax.com

joimax[®], Inc.

275 E. Hacienda Avenue
Campbell, CA 95008 USA

PHONE +1 408 370 3005
FAX +1 408 370 3015
MAIL usa@joimax.com
NET www.joimax.com

Patents pending





Cardinal Tower
12 Farringdon Road
London
EC1M 3NN

EDITORIAL
Tel: +44 (0) 20 7452 5133
Fax: +44 (0) 20 7452 5050

SALES
Tel: +44 (0) 20 7452 5101
Fax: +44 (0) 20 7452 5601

E-mail: info@touchbriefings.com
www.touchbriefings.com